

Dr. Patils Dental Clinic

Dr. Yashashri Manish Patil

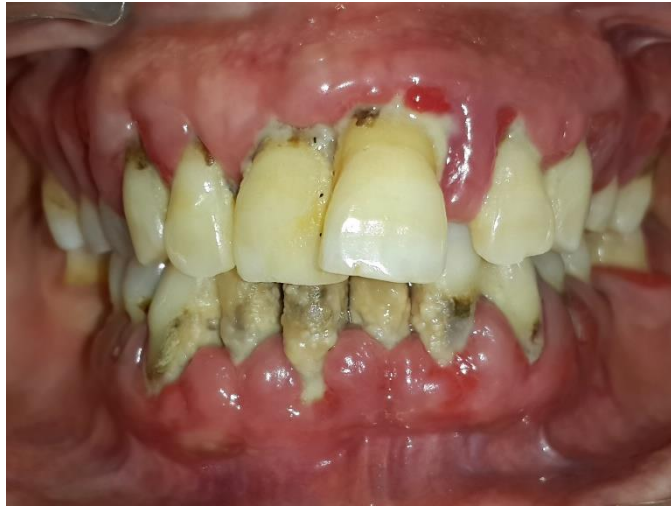B.D.S. (Nair Hospital)

M.D.S. (Periodontology and Implantology)

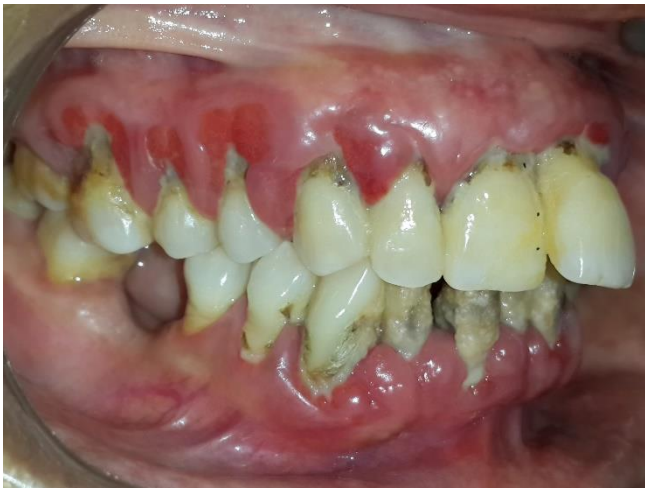Specializes in Gum Surgeries and Implantology

Contact No: [083569 47807](tel:08356947807)

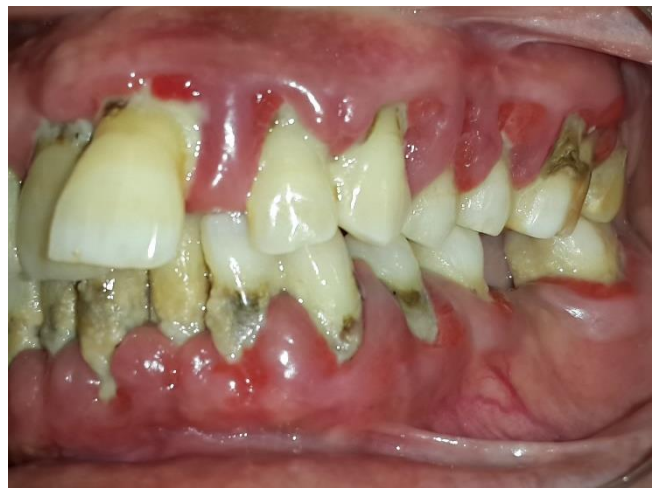SCALING AND ROOT PLANING – PRE OPERATIVE



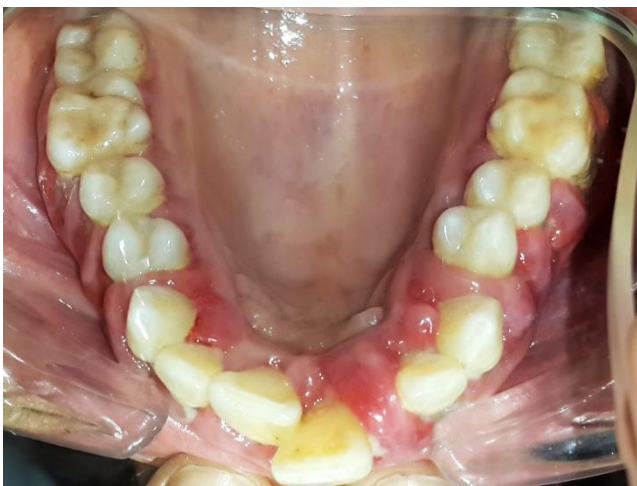Frontal



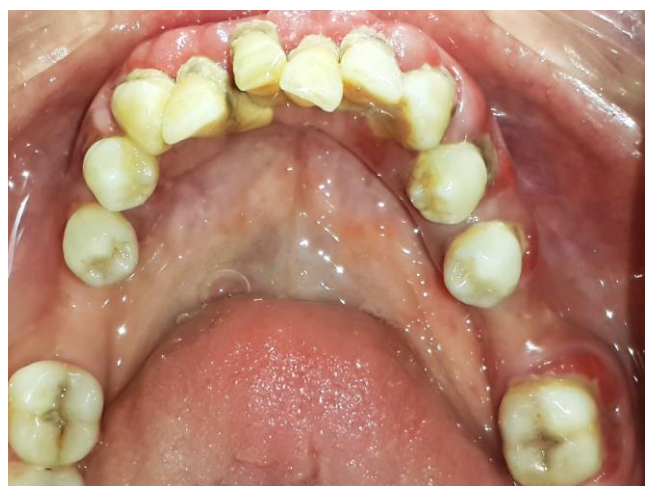Right lateral



Left lateral

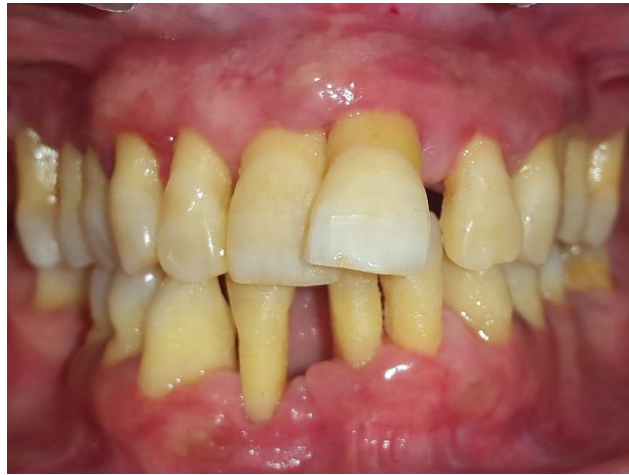

Maxillary occlusal

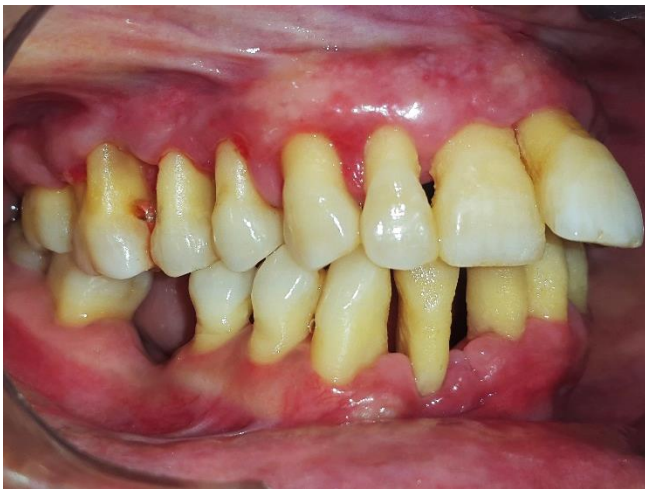

Mandibular occlusal

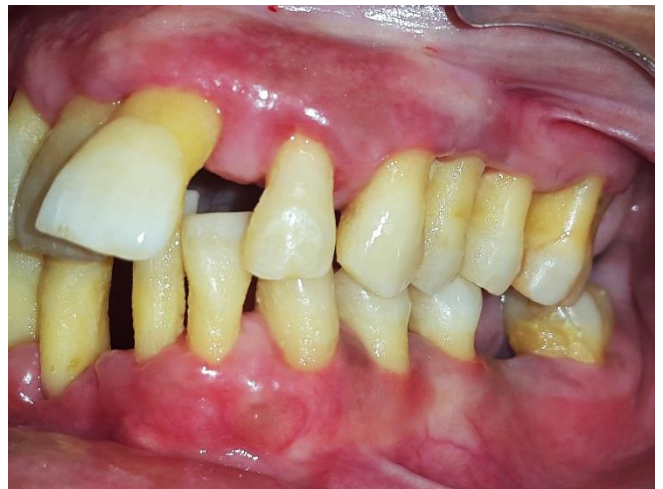SCALING AND ROOT PLANING – POST OPERATIVE



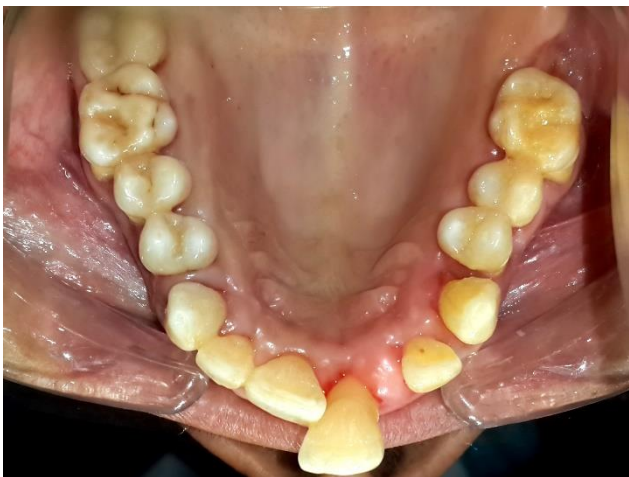Frontal View



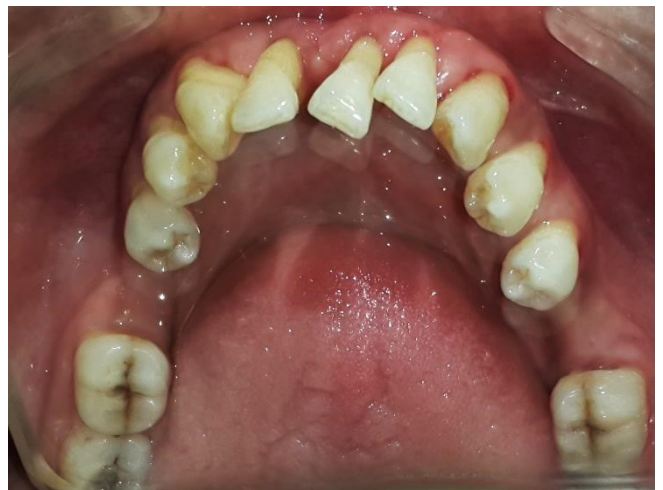Right lateral



Left lateral

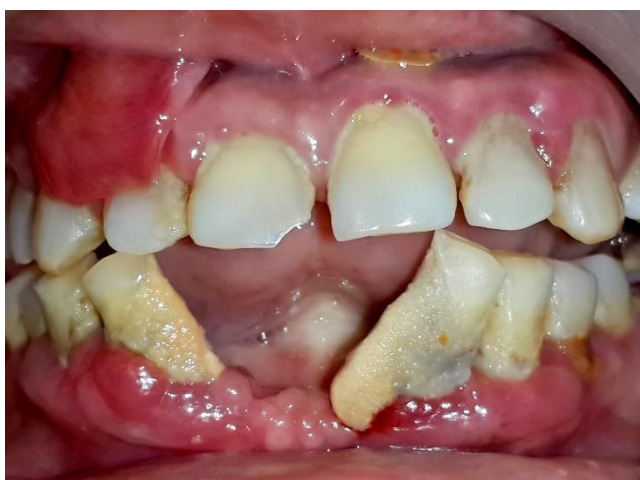

Maxillary occlusal

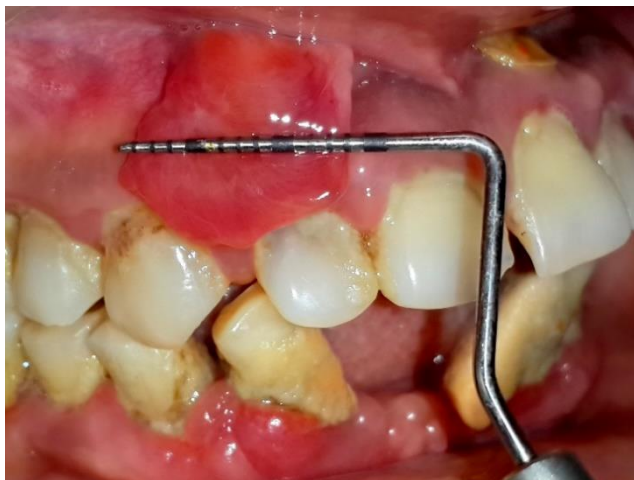

Mandibular occlusal

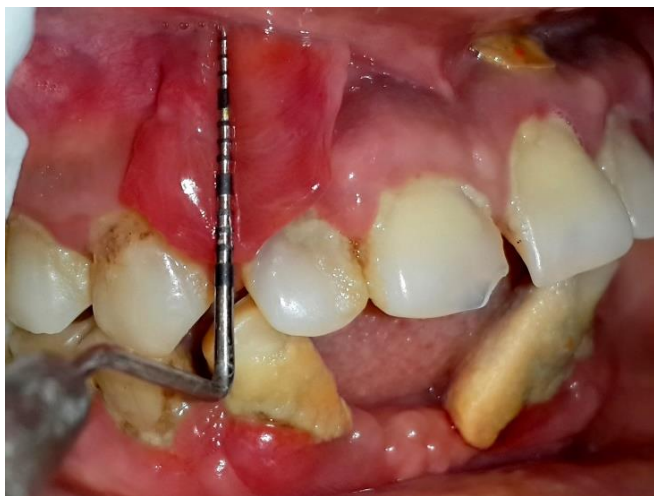BIOPSY



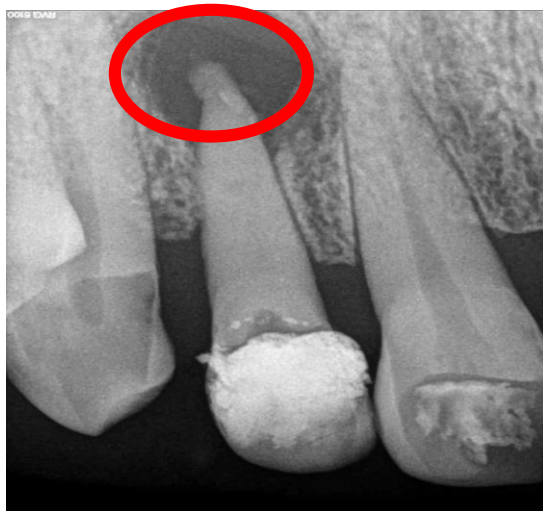Pre operative



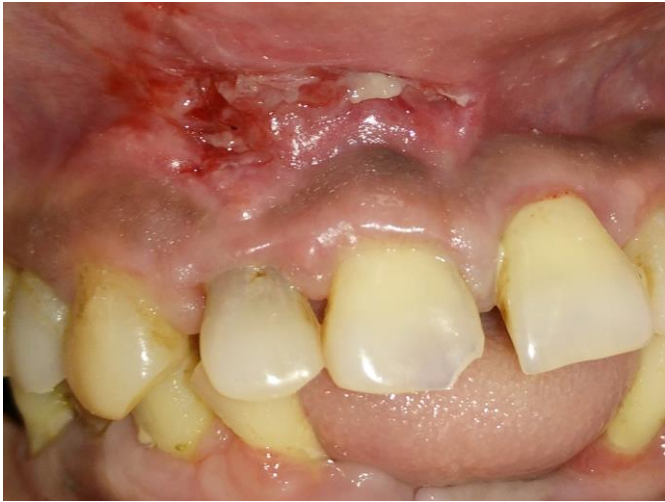Pre operative horizontal dimensions of the lesion



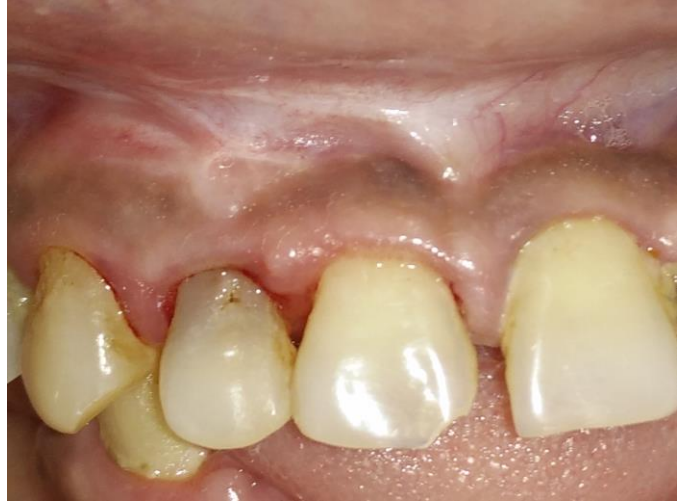Pre operative vertical dimensions of the lesion



IOPA w.r.to 23 showing periapical radiolucency

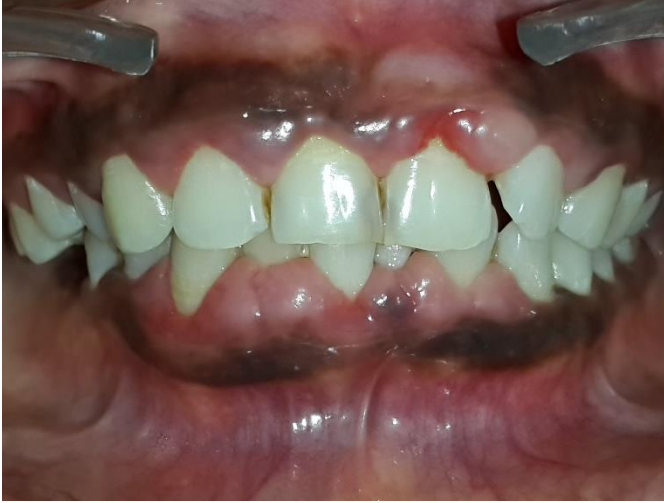

1 week post operative

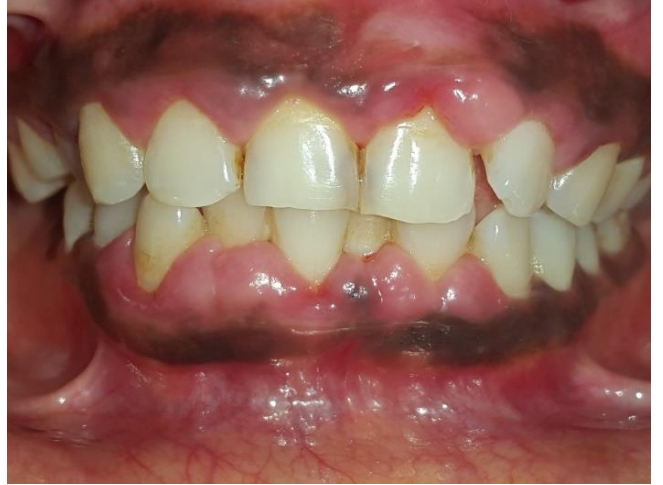

6 months post operative

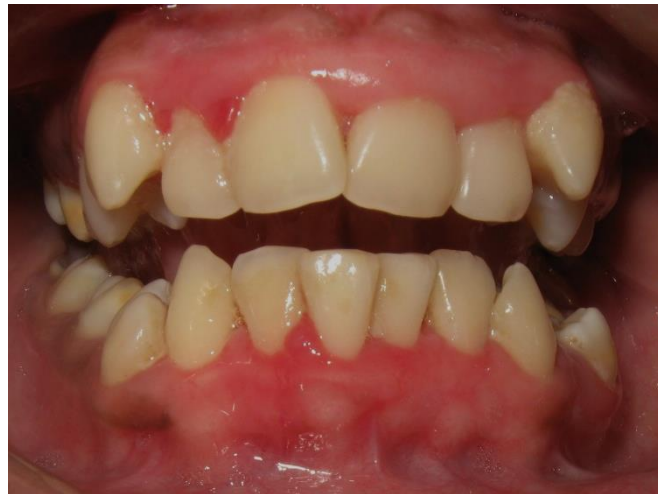GUM SHAPING



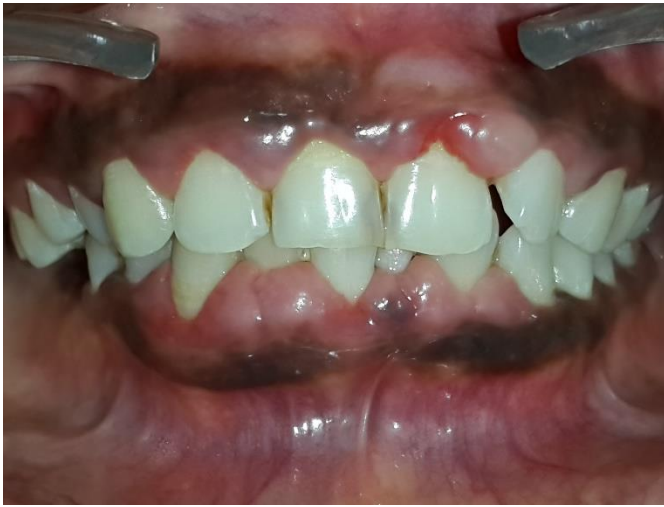Pre operative



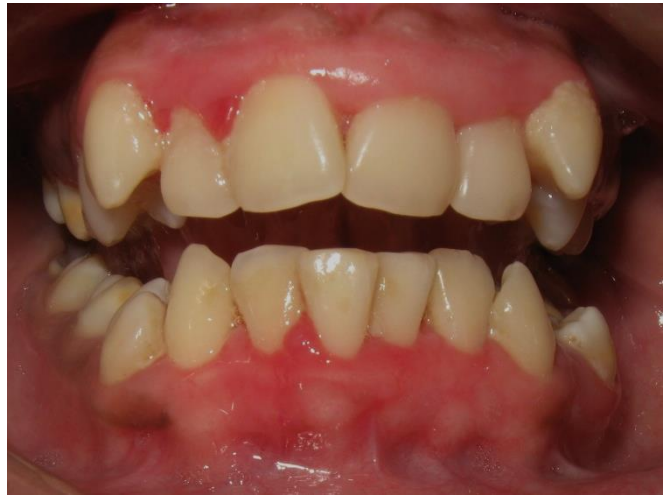1 week post scaling and root planing



One month post surgical view

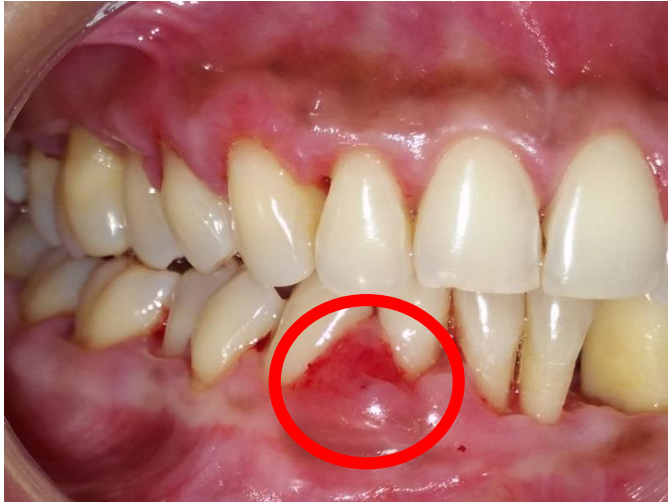

Pre operative

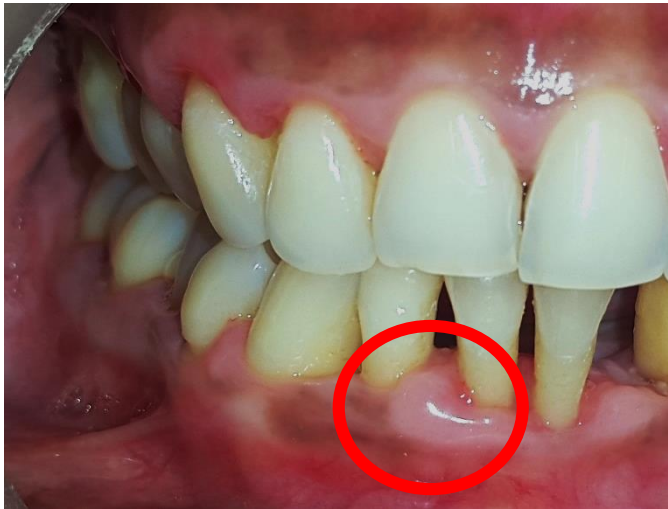

One month post surgical view

ABSCESS DRAINAGE

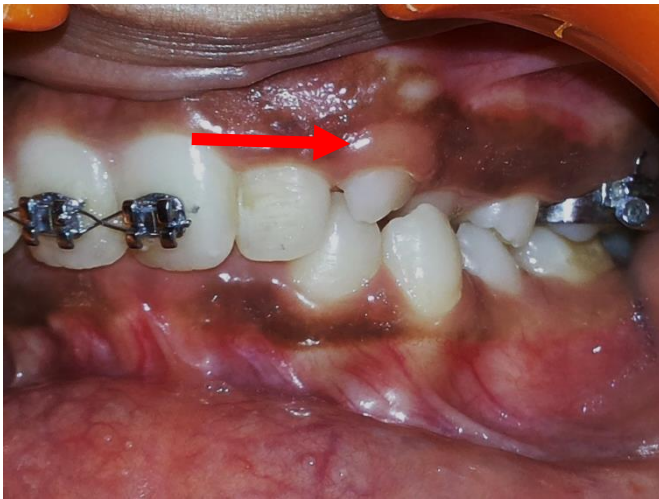

Pre operative showing
periodontal abscess with 42

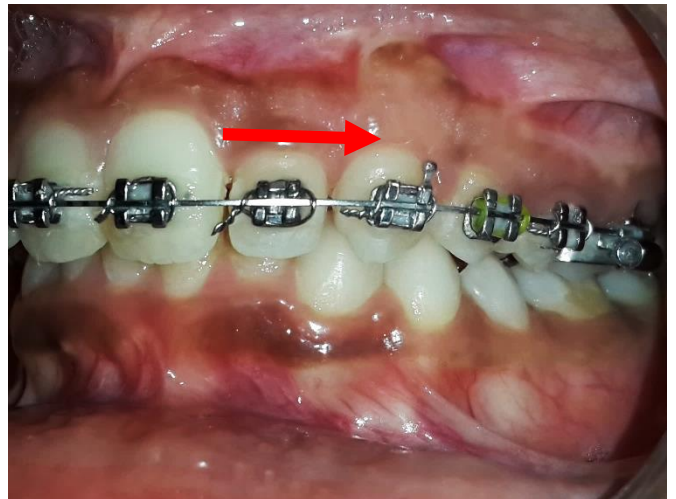

2 weeks post operative

APICALLY DISPLACED FLAP FOR CROWN LENGTHENING

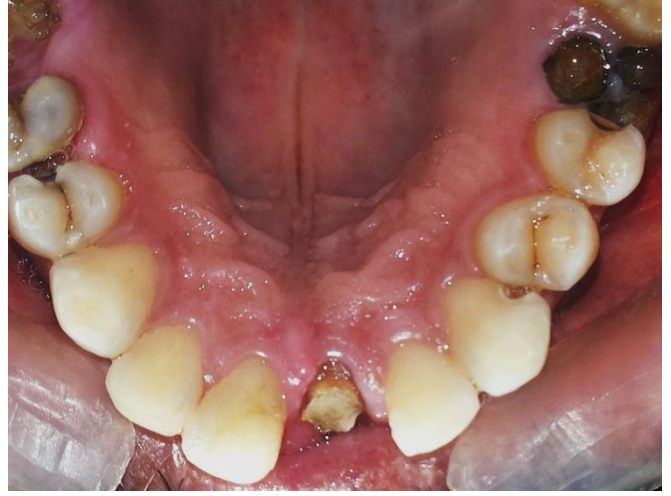
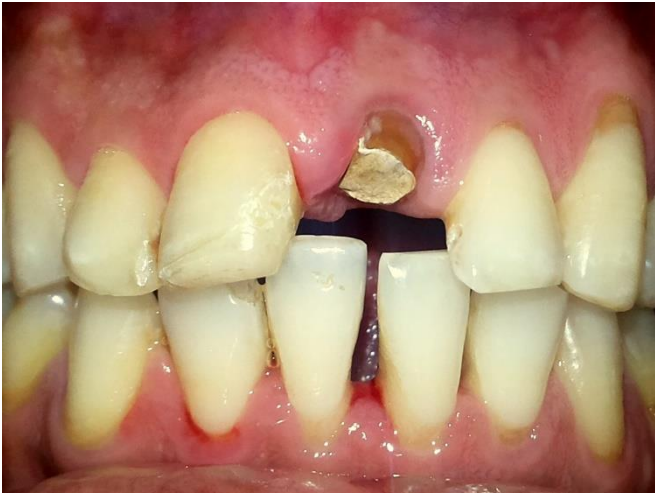
Pre operative view

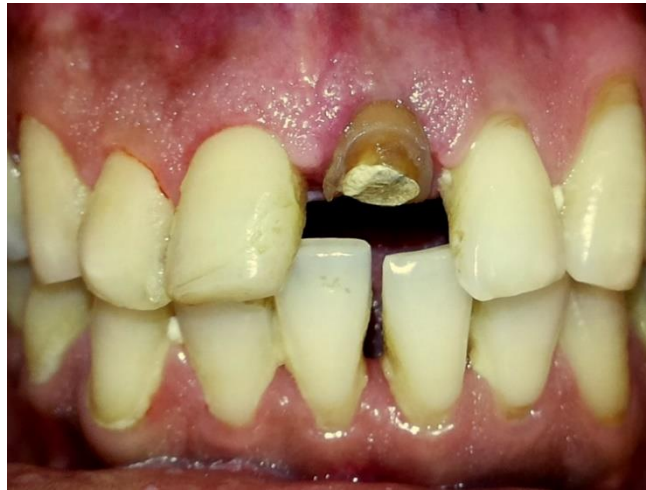

9 months post operative

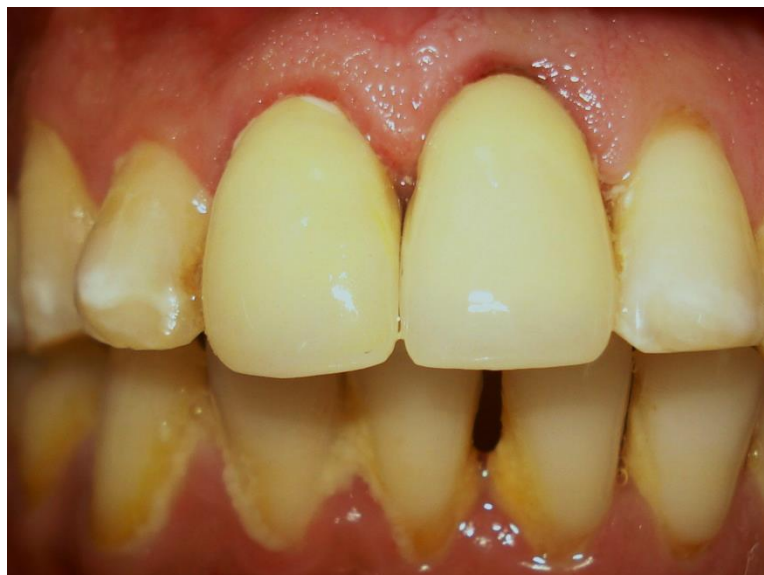OSSEOUS CROWN LENGTHENING



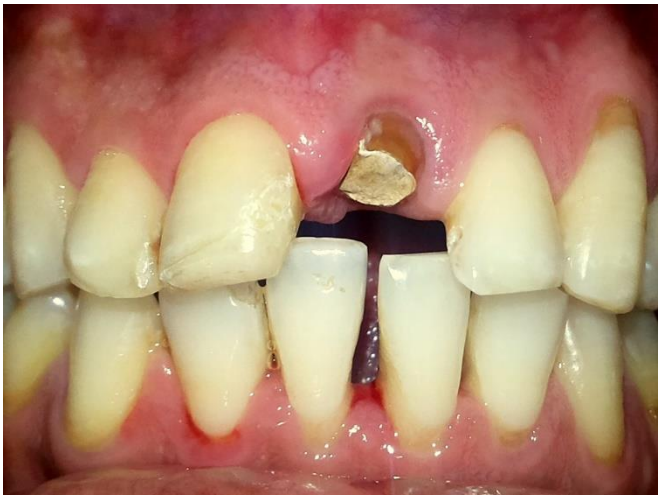Pre operative view showing reduced crown length with 21 on facial and palatal aspect



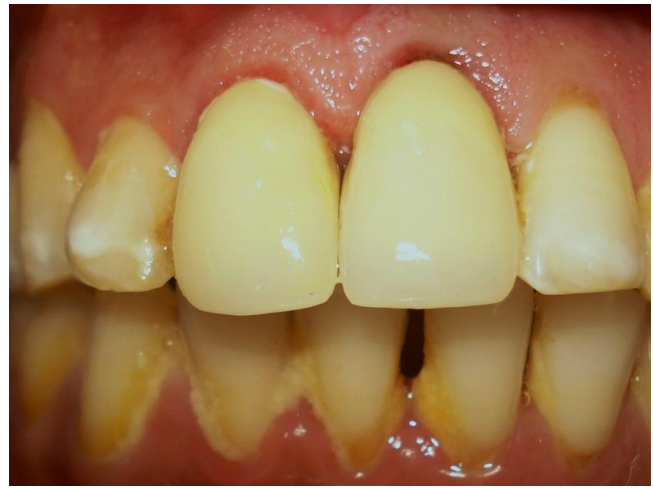Post operative



Prosthesis given with 21

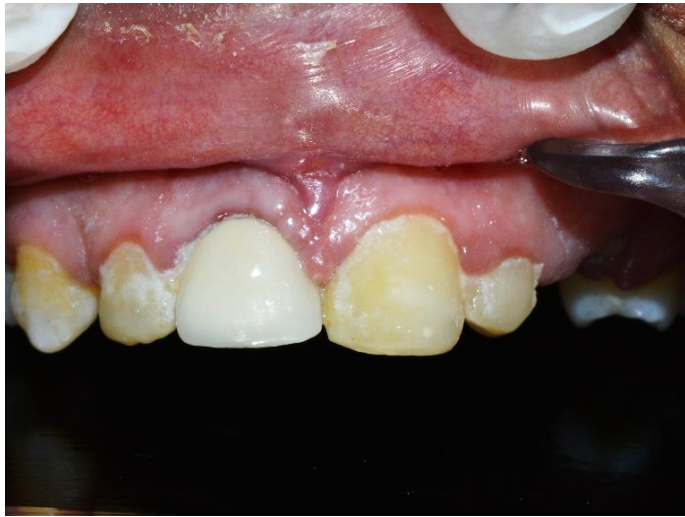

Pre operative

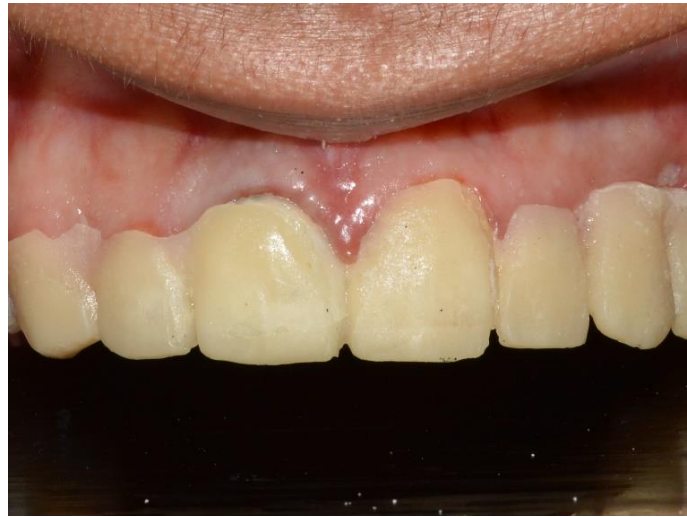

Post operative

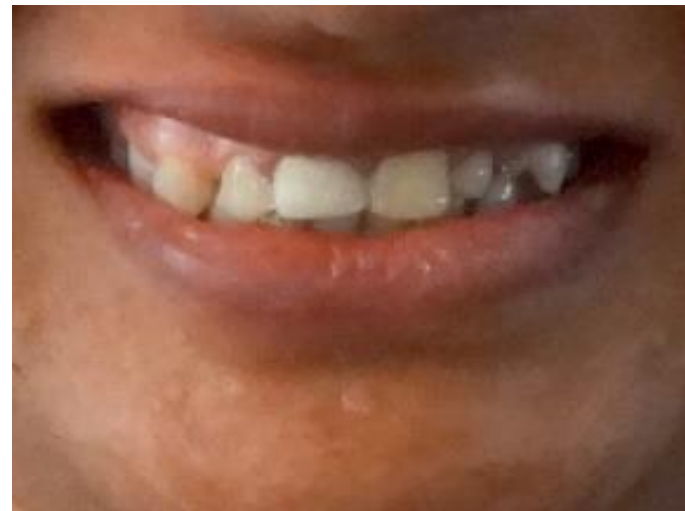FULL MOUTH REHABILITATION



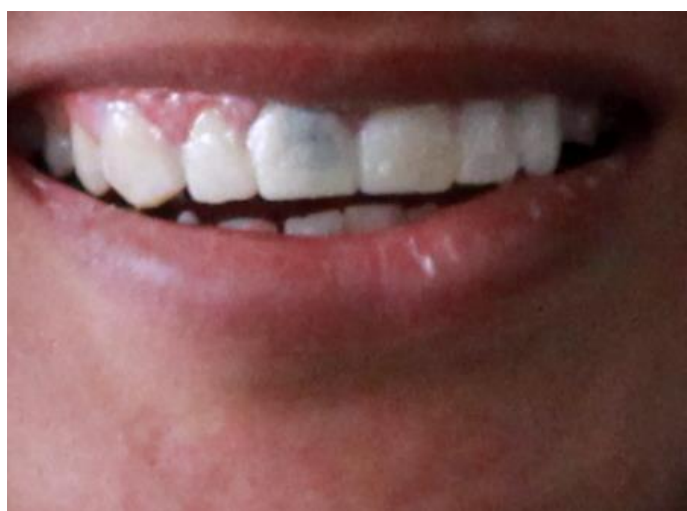Pre operative



Post operative after cementation
of temporary

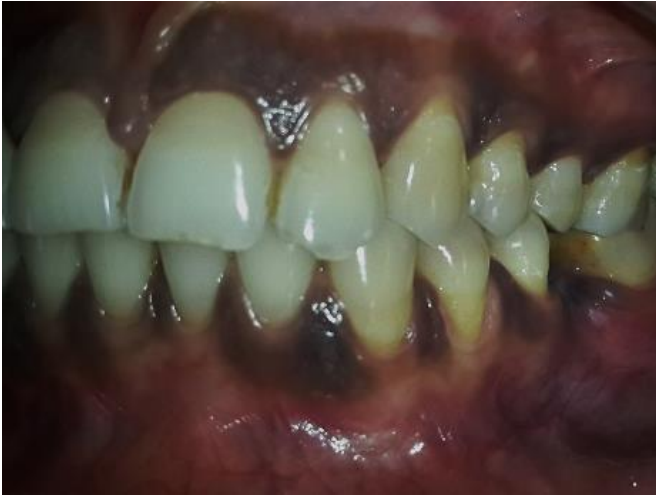

Pre operative

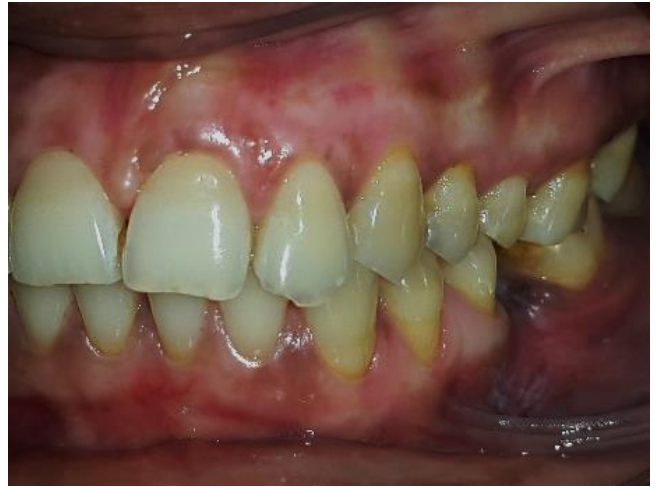

Post operative

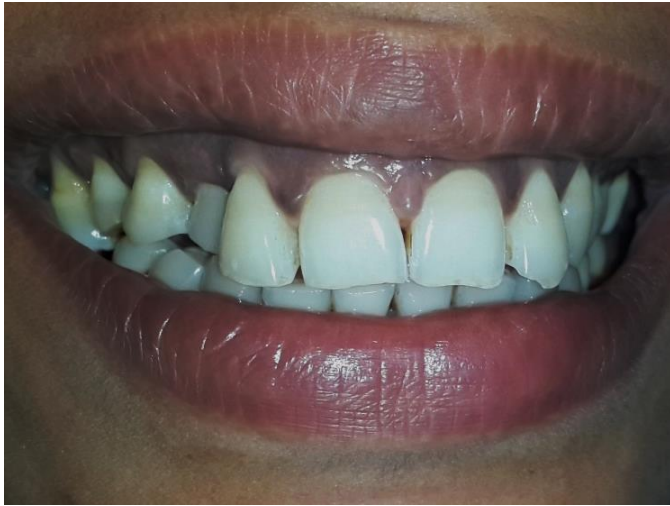GINGIVAL DEPIGMENTATION



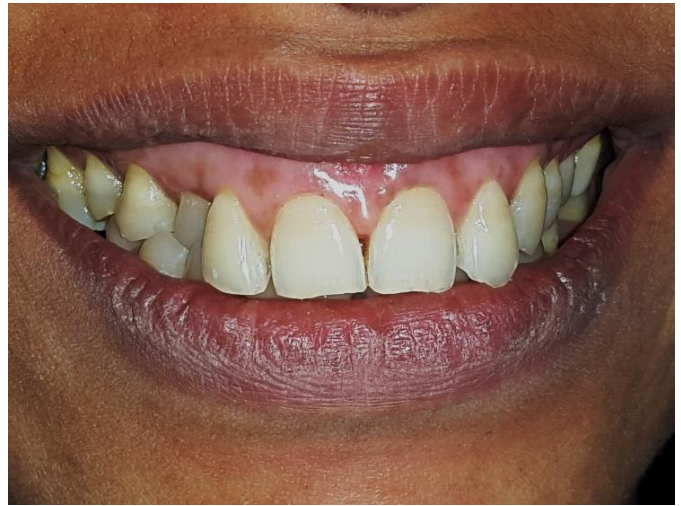Pre operative left lateral



2 months post operative left lateral

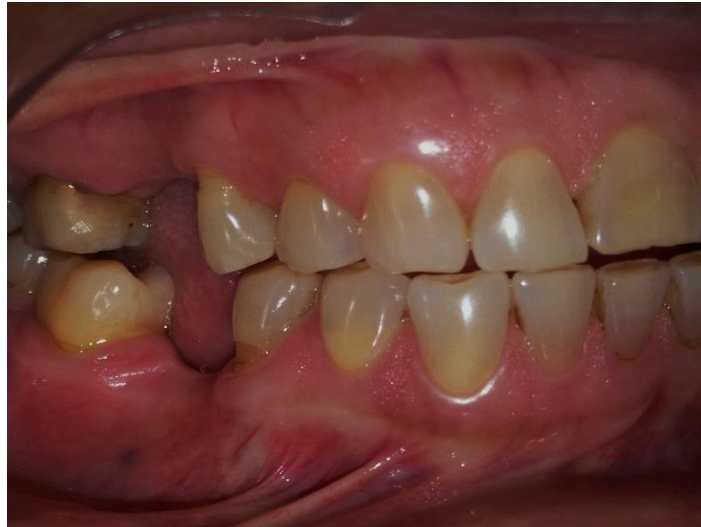

Pre operative

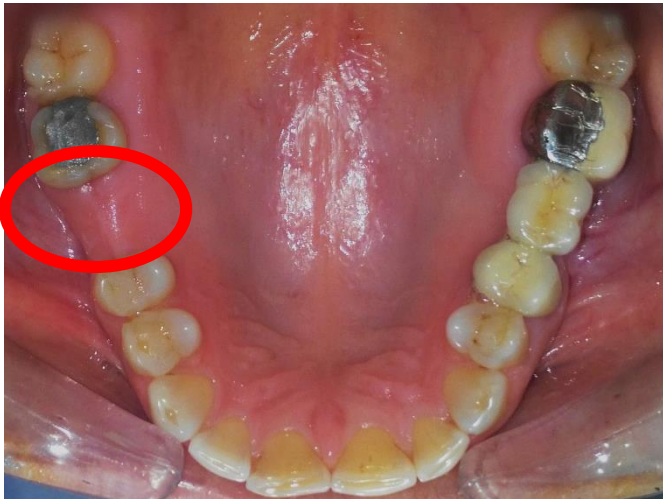

2 months post operative

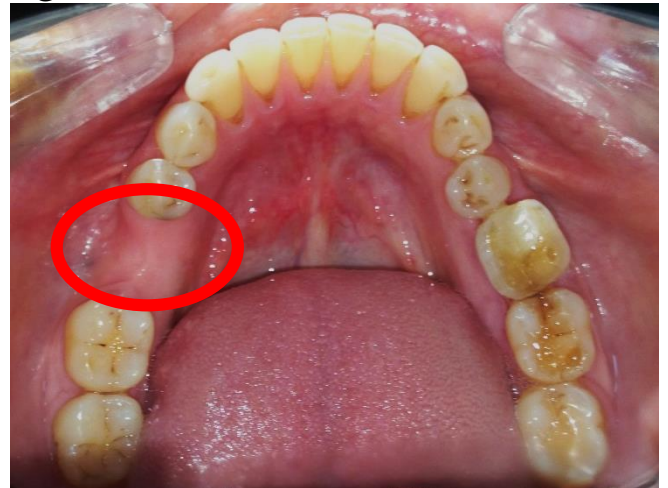
DENTAL IMPLANT WITH 16 AND 46



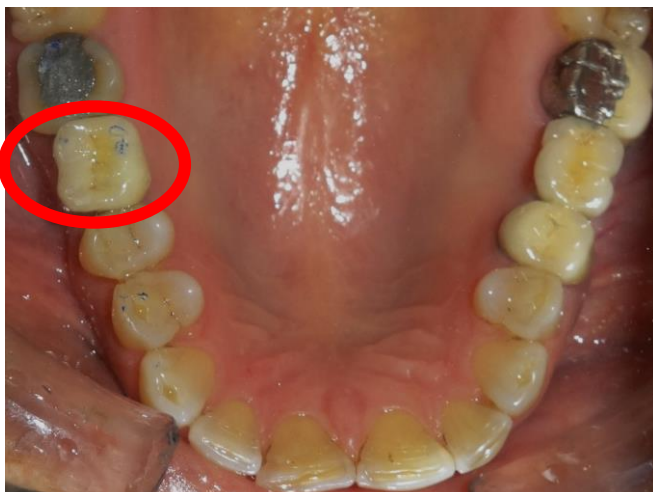Pre operative view showing missing 16 and 46



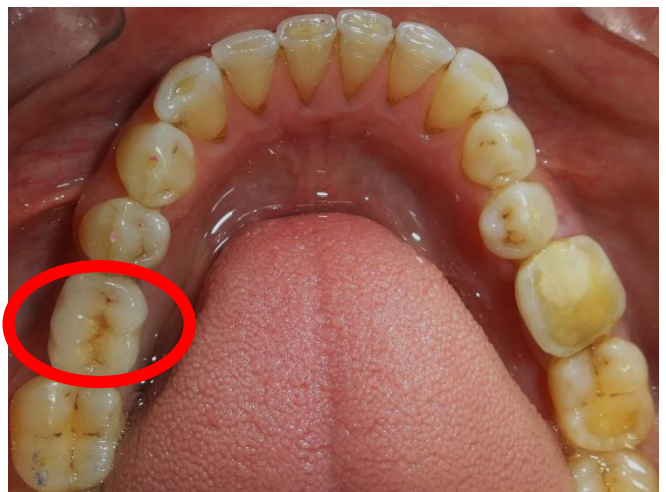
Pre operative maxillary occlusal view showing missing 16



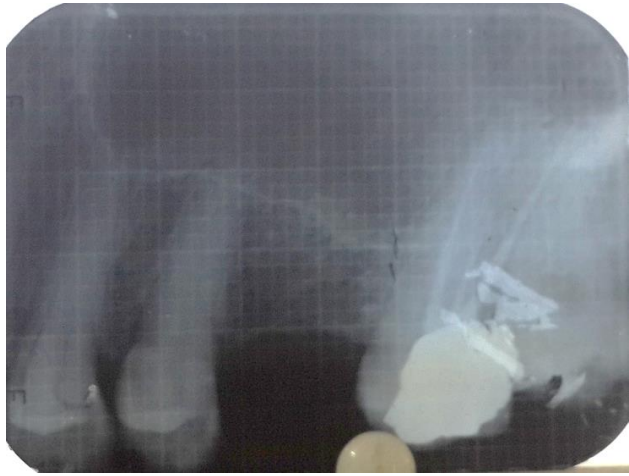Pre operative mandibular occlusal view showing missing 46



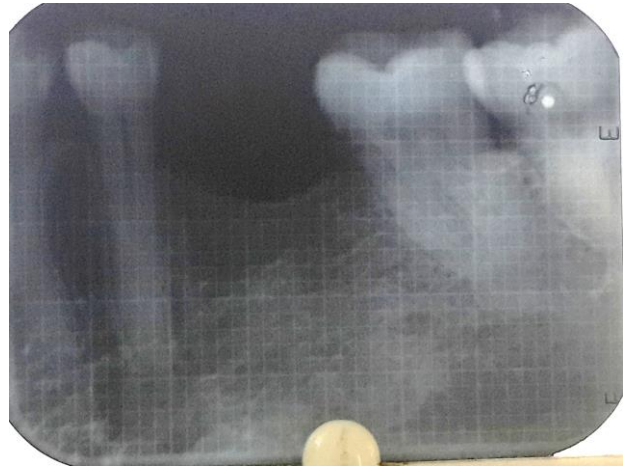
16 – prosthesis cemented



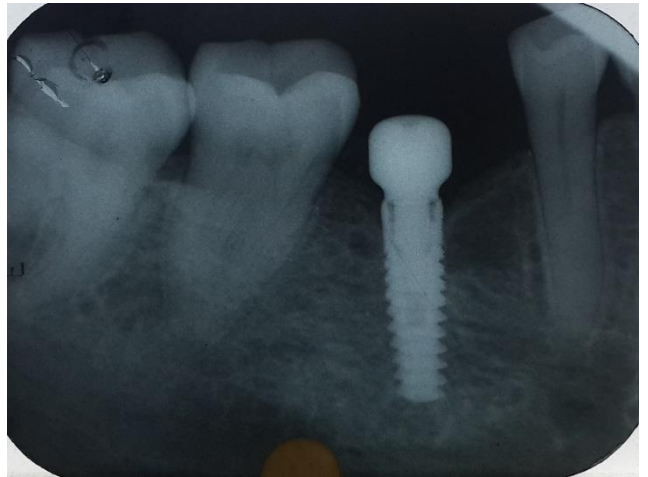
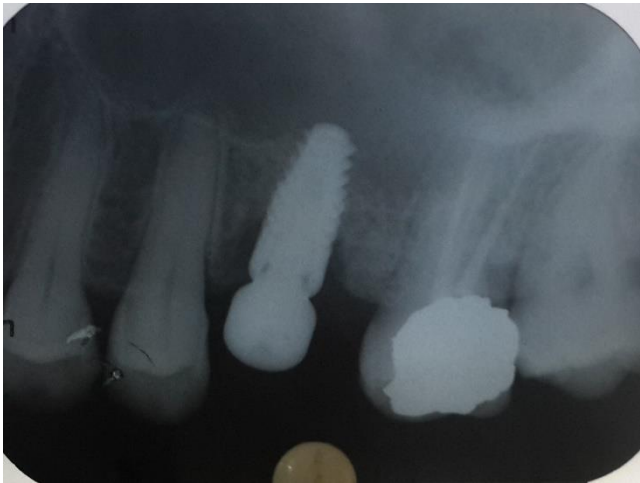46 – prosthesis cemented



Pre operative maxillary radiograph



Pre operative mandibular radiograph



Maxillary and mandibular radiograph with gingival former in place